第八十二期 issue 82
Mar-Apr, 2013

聖保祿醫院
St. Paul's Hospital

NewsLetter 院訊

Episodic Patella Dislocation (EPD)

CME Presentation Recap:

- Clinical Opthalmology Updates
- Management of Stroke: Current Updates

MESSAGE
FROM THE MEDICAL SUPERINTENDENT

In memory of our beloved colleague Pinky

Pinky left us all of a sudden, at a young age of 36, leaving behind a husband and two kids. Life was as usual in the morning of March 9, when she was handing over duties with fellow nurses at the station of our Maternity Ward. An intense headache overwhelmed her. Colleagues quickly brought her to the Out Patient Department, where she soon lapsed into coma. Doctors and nurses started resuscitation, intubation, emergency CT scan, neurosurgical consultation, then operation and intensive care. She never came back.

Colleagues were shocked, family members devastated. Doctors volunteered to help, not only trying their best to save Pinky but also to provide psychological counseling to co-workers. Hospital Management took up the supporting role, attending to family members' needs and emotions of other staff. Appropriate response to media enquiries was called for, as was internal communication to keep everybody updated in such a time of trauma, grief and disbelief. Sisters came to give spiritual care, as well as engaging a Catholic Father for the baptism of Pinky, who was given the Christian name of Paula, after St. Paul.

Despite the huge effort, brain death ensued. At the request of the family, we quickly contacted the Hospital Authority for the possibility of organ transplant, something that St. Paul's Hospital had never done in its entire history, and possibly only the second case in a private hospital in Hong Kong. Necessary tests were quickly arranged. Detailed explanation to the family members, and the elaborate consent process were done. There was incessant communication concerning Operating Theatre preparedness, the issue of considerable expenses (which Sister kindly agreed to absorb, and doctors agreed not to charge), transportation arrangements, and the logistics of QMH surgeons operating with our hospital's anaesthesiologists and OT nurses. Finally the useful organ was harvested, and Pinky saved a life with the most precious gift that one can ever give.

I was in the OT that late evening. The professionalism of our doctors and nurses was most exemplary, despite the immense emotional burden of dealing with their own colleague. I was particularly moved by the meticulous care that they took to clean and dress Pinky afterwards, both in honour of her and for the sake of relatives. When I emerged from the changing room after midnight, I met two doctors waiting in the staff lounge for hours, just to pay the last respect to Pinky on her way out.

A memory corner was set up, where fellow colleagues prayed for Pinky and wrote down their thoughts for her. Donations were collected for the family. A Requiem Mass was held. When the long line of colleagues and Sisters took turns to bless and shake hands with Pinky's relatives, amid chanting hymns, tears could not be stopped. I was barely holding back mine, some ten years after I said goodbye to colleagues succumbing to a novel infection.

In the words of Father Kwan, Pinky would want to see us serving our patients even better, like what she had done to others. And I am sure Paula will smile when St. Paul's Hospital goes from strength to strength. May she rest in peace in the arms of God.

Dr. William Ho
Medical Superintendent

MEDICAL ARTICLE

Dr. Lau Yip Kwong, Francis
Specialist in Orthopaedics & Traumatology,
St. Paul's Hospital

Episodic Patella Dislocation (EPD)

Episodic patella dislocation is not an uncommon injury and occurs with significant regularity. It accounts for 2-3 % of all knee injuries [1]. But many believes that it is under estimated because most of the time, the patella reduces itself and is treated as a non specific knee sprain. Proper evaluation and treatment is needed to prevent misdiagnosis, future dislocation as well as other consequences from the dislocation, especially osteoarthritis of the patellofemoral joint.

The patella is the largest sessamoid bone in the body (12cm square), with the thickest cartilage (up to 6mm). This is specially designed to bear the great compressive and shear forces acting on it in knee movement, so as to increase the leverage and to centralize the divergent forces from the four heads of the quadriceps. Its stability depends on bony and soft tissue constrains.

The mechanism of injury is usually a valgus stress on the knee, with internal rotation of the femur while the foot is fixed on the ground [2]. In the majority of cases, the patella will reduce itself leaving only pain and swelling mostly over the medial side. Occasionally the patient may notice the dislocation and reduction process, otherwise there will only be a feeling of giving way and pain. In rare instances when the patient presents with unreduced patella, it can be easily reduced by relaxation of the quadriceps with hip flexion and application a medially directed force on the patella.

Physical examination will only reveal tenderness over the medial side of the patella. Apprehension test would be difficult to perform at this stage due to the tenderness. Palpation from patella down to femoral epicondyle can detect the site or sites of injury to the most important structure- the MPFL, medial patellofemoral ligament. This ligament has a broad origin on the proximal part of patella medially, runs in the second layer of the knee structures and inserts in between the medial femoral epicondyle and

the adductor tubercle [3]. Biomechanical studies have shown that this is the major ligamentous restraint against lateral patella dislocation. It is estimated to contribute 50-60% of restraints [4-6] and it is torn in up to 100% of cases in acute dislocation. Frequently it is disrupted at more than one sites and hence made primary repair impossible. [7], (54% at patella, 12% midsubstance, 34% at femur). Other concomitant injuries e.g. ACL and MCL have been described and should therefore be examined for. Generalized ligamentous laxity (Beighton Score) and signs of malalignment syndrome (anteverted femoral neck, valgus knee, external tibial torsion, pronated foot) should also be documented.

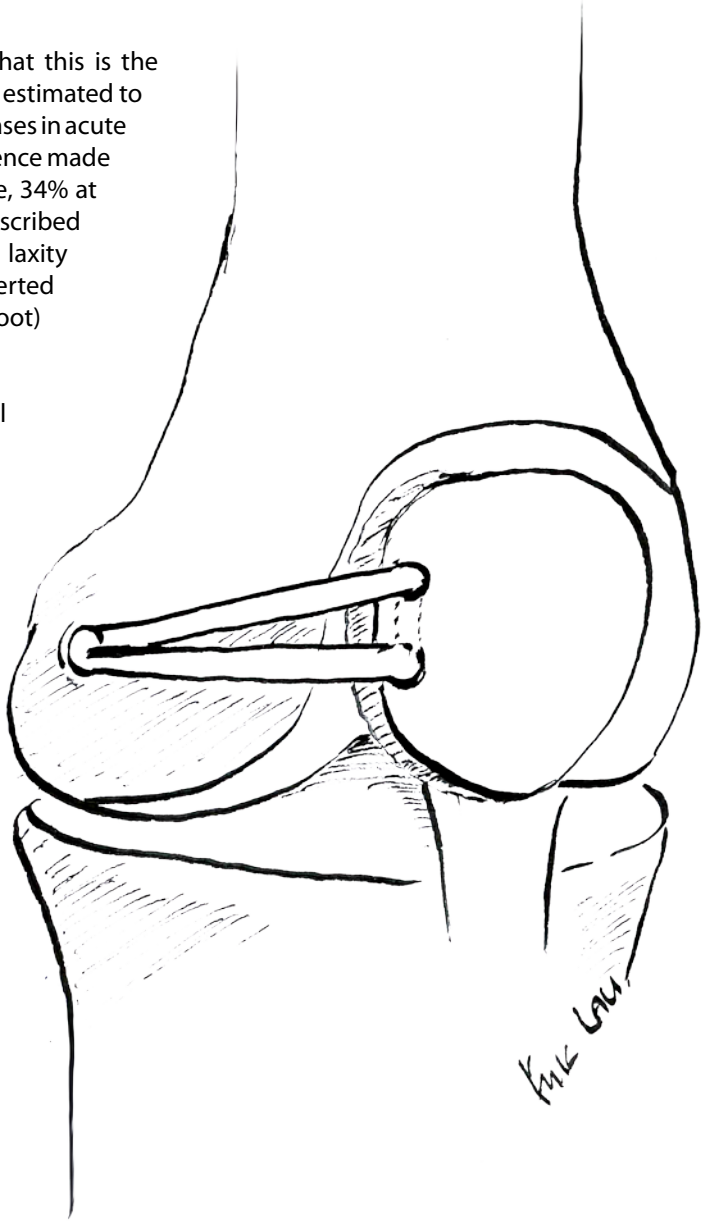

At the acute stage, the only concern is to look for osteochondral injury which may require fixation or excision. Osteoarthritis of the patellofemoral joint will follow if this is not treated properly. Pain on climbing stairs is a poorly tolerated condition especially in this locality where buildings are high-rise. MRI is recommended since X-ray usually underestimates the size and severity of cartilage injury [8]. Other imaging must also be performed to identify the 4 classic factors now believed as the main contribution to patella instability- trochlea dysplasia, patella alta, abnormal tibial tubercle-trochlear groove distance (TT-TG) and patella tilt [9-11]. These are the more important 'localized' factors, comparing to those described in malalignment syndrome, which can all be treated surgically in an alacarte manor.

In a previously well balanced patella, only episodically dislocated from a twisting injury, the 4 classic factors are usually not far from normal range. Conservative treatment is reasonable for first time dislocation since the recurrence rate ranges from 15 to 44% [10]. After the acute injury has subsided, patient with persistent apprehension or recurrent dislocation, MPFL reconstruction is the treatment of choice. There are several ways to do this but my preferred method is anatomically with a semitendinosus or gracilus graft in a double bundle fashion [3] with patella tunnel and one biofixation at femur. Details of the technical side would not be discussed here due to the limited space.

Reference

1. Stefancin JJ, Parker RD. First time traumatic patella dislocation: a systemic review. Clin Orthop Relat Res. 2007; (455): 93-101
2. Sillanpaa P, Mattila VM, Iivonen T, et al. Incindence and risk factors of acute traumatic primary patella dislocation. Med Sci Sports Exerc. 2008; 40: 606-11
3. Amis AA, Firer P, Mountney J, Senavongse W, Thomas NP. Anatomy and biomechanics of the medial patellafemoral ligament. Knee. 2003 Sep.: 10(3): 215-20
4. Con Ian T, Garth WP J, Lemons JE. Evaluation of the medial soft tissue restraints of the extensor mechanism of the knee. JBJS Am 1993; 75: 682-93
5. Desio SM, Burks RT, Burks RT, Bachus KN. Soft tissue restraint to lateral patellar translation in the human knee. Am J Sports Med. 1998; 26: 59-65
6. Hautamaa PV, Fithian DC, Kaufman KR, et al. Medial soft tissue restraint in lateral patellar instability and repair. Clin Orthop. 1998: 174-82
7. Elias DA, White LM, Fithian DC. Acute lateral patella dislocation at MR imaging: injury patterns of medial patella soft tissue restraints and osteochondral injuries of the inferomedial patella. Radiology 2002 Dec.; 225(3): 736-43
8. Stefancin JJ, Parker RD. First time traumatic patella dislocation: a systemic review. Clin Orthop Relat Res. 2007; 455: 93-101
9. Dejour H, Walch G, Nove-Josserland L, Guier C. Factors pf patella instability: an anatomic radiographic study. Knee Surg Sports Traumatol Arthosc. 1994; 2(1): 19-26
10. Maenpaa H, Letto MU. Patella dislocation: the long term results of non-operative management in 100 patients. Am J Sports Med. 1997; 25(2): 213-37

Clinical Opthalmology Updates

18th December 2012

All you need to know about Acute Angle Closure Glaucoma

Dr. Chan Chia Chieh, Orlando
Specialist in Ophthalmology

Acute angle closure glaucoma (AACG), also called 'acute glaucoma' is a disease in which there are sudden increases in eye pressure. This usually occurs in one eye and is associated with sudden loss of vision. Acute glaucoma happens when aqueous humor (the liquid in the eye) is unable to drain correctly. It is more common in elderly population (female to male ratio 2:1) with long-sightedness. Symptoms include severe pain in the eye, redness, decreased vision, and sometimes nausea and vomiting. An acute attack is precipitated by partial dilatation of the pupil, which blocks the drainage of fluid out of the eye. The pressure inside the eye (intraocular pressure) rises quickly. Repeated attacks may also occur and may progressively reduce the visual field. Besides high intraocular pressure (IOP), other signs may include conjunctival injection, corneal epithelial edema, mid-dilated non-reactive pupil and shallow anterior chamber.

Acute angle closure glaucoma is an ocular emergency that require immediate treatment. The goals of treatment are to lower the pressure as soon as possible so as to reduce the risk of permanent optic nerve damage, and to prevent further attacks. Initially, AACG is treated with a range of medicines that may be given as eyedrops or pills. Intravenous medications may also be used in some cases where IOPs may be critically high. However, the definitive treatment for most cases of angle closure glaucoma is laser peripheral iridotomy.

During an acute attack, the cornea is usually edematous secondary to the high IOP. Therefore, topical glaucoma eyedrops (such as beta blockers, alpha adrenergic agonists, and carbonic anhydrase inhibitors) may be used in combination first to lower the eye pressure. Once the eye pressure has been lowered, cholinergic eyedrops are used to stretch the iris and make it easier for the laser to produce a hole in the iris. Oral and intravenous medications may be necessary when topical medications fail to adequately lower the IOP.

A laser peripheral iridotomy produces a hole in the iris to break the pupillary block and acute closure of the drainage angle. Aqueous is allowed to make its way to the trabecular meshwork, thereby lowering the IOP. Instances where significant cataract is present during an acute angle closure attack, early cataract surgery may also be considered after reduction of IOP to prevent repeated attacks in the future.

In summary, acute angle closure glaucoma is a condition that requires immediate treatment. Rapid diagnosis, immediate intervention, and referral can have profound effects on patient outcome and morbidity.

Ophthalmic Emergencies in the Paediatric and Adolescent

Dr. Wu Kai Wah, Patrick
Specialist in Ophthalmology

Various eye conditions happening in the paediatric and adolescent age group are emergencies, where prompt referral to an ophthalmologist for action and treatment is essential. These conditions may either be potentially blinding, endangering the life of the subject, or they may severely affect the visual development of the individual.

The clinical types can include the followings:

1. Trauma – in any young patient with history of injury to the eyeball, high index of suspicion for globe rupture is essential. History taking with special attention to detect prevarications is important, and the possibility of 'non-accidental injury" should be kept in mind. During the examination, even a slight distortion of the pupil should alert the doctor to exclude the possibility of eyeball perforations.

2. Orbital cellulitis –chemosis, proptosis, defective ocular movements and systemic upset are important signs to differentiate it from the milder entity of pre-septal cellulitis. Admission for close monitor is necessary. Orbital imaging should be arranged promptly. Most will require intra-venous antibiotics, and surgical toilet might also be necessary in selected cases.

3. Keratitis (corneal ulcer) – any acute "white spots" within the "black part" of the eye (cornea) is a sinister sign, especially if there is a history of trauma or contact lens wear, and/or associated conjunctivalhyperemia. Prompt referral to an ophthalmologist is essential. Investigations like ulcer scraping for culture/ sensitivity tests followed by treatment should be arranged as soon as possible. Delayed action may result in severe consequences like dense corneal scars, eyeball perforations and endophthalmitis.

4. Acute onset convergent squint (esotropia) – The possibility of sixth nerve palsy secondary to intracranial pathology should be excluded. Moreover, acute esotropia in a young kid aged 3-5 is specifically important. As the child is still visually immature, acute esotropia will result in active cortical suppression in the brain. Prompt referral to an ophthalmologist is advisable, as prompt treatment is essential to preserve the child's sensory fusion & stereopsis, and to prevent amblyopia development. As it has been shown that this sensory deterioration can occur within days to weeks, acute esotropia in this age group is regarded as a "daytime emergency" by paediatric ophthalmologists.

5. Nystagmus - any intermittent/ continuous "new-onset" nystagmus require neuro-imaging to exclude lesions in the brain.

6. Leukocoria– Any observed sign of "whitish pupillary reflex" require prompt ophthalmic referral. The underlying causes can include cataract, intra-ocular inflammation, retinal granuloma, or even ocular tumours like retinoblastoma. Prompt investigation and management by an ophthalmologist is important.

In conclusion, proper management of ocular emergencies in the young age group depends on the knowledge and ability to identify them. Prompt referral, investigation & treatment will save the sight as well as lives of the kids.

Cosmetic Surgery of Eyelid

Dr. Cheng Pak Man, George
Specialist in Ophthalmology

The sub-specialty of Oculoplastic Surgery in Ophthalmology is treating both functional and cosmetic eye surgery. Cosmetic eyelid surgery is very popular in Hong Kong. In this presentation, we will cover (1) Anatomy of eyelid (2) Ptosis Surgery (3) Double lid crease Surgery (4) Blepharoplasty Surgery.

Eyelid Anatomy

Eyelid has two lamella – Anterior Lamella & Posterior Lamella
Anterior Lamella has: = skin + orbicularis muscle
Posterior Lamella has: = tarsal plate + levator muscle +aponeurosis +Muller's muscle + conjunctiva
In assessment of patients, we need to realized that "Eyelid is part of the face"
- Upper eyelid = lower limit of the upper face
- Lower eyelid = Upper limit of lower face
Eyelid problem can be due to a localized cause or a general facial problem.Detail assessment of the whole face is the most important step.

PTOSIS

- is the abnormal low position of upper eyelid
• Mild Ptosis = 2 mm
• Moderate Ptosis = 3mm
• SeverePtosis = 4mm or more
Must rule out pseudo-ptosis.:
Common Causes of pseudo-ptosis
(1) Dermatochalasis - excess skin only
(2) Brow ptosis
(3) Microphthalmos - small eyeball
(4)Contralateral lid retraction
Careful examination of the height of the eyelid margin is most important to ruleout pseudo-ptosis.

Causes of True Ptosis:

• Aponeurotic
  – senile ptosis – post-operative
• Myogenic
  – congenital ptosis – senile ptosis
  – muscular dystrophy
• Neurogenic
  – e.g. third nerve palsy
• Mechanical
  – e.g. lid tumour

Choice of ptosis surgery:

• Cause of ptosis • Amount of ptosis
• Levator muscle function • Amount of ptosis
• Levator muscle function

Most common ptosis surgery

1. Fasanella-Servat Procedure – for cosmetic ptosis
2. Mullerectomy
3. Aponeurotic Repair – for senile ptosis
4. Levator muscle Resection – for senile or mild congenital ptosis
5. Frontalis Brow Suspension – for severe congenital ptosis

Double Lid Crease

Lid Crease is formed by the attachment of levator muscle to the pre-tarsal orbicularis muscle and skin. With contracton of levator muscle, the complex (tarsus + pretarsal orbicularis + pretarsal skin) move as a whole block. It will form a double lid crease. Without this attachment, patient will have a single lid crease. The basic principle of double lid crease surgery is to establish this attachment.

Two common methods forDouble lid crease Surgery

1. Open method
- With skin incision
- Advantage : can excise excess skin and fat and more permanent effect
- Disadvantage : risk of skin scarring

2. Suturing method
- Can use anterior approach or posterior approach
- Use suturing only
- Advantage : no skin scarring
- Disadvantage : may not be permanent and may need suture again

Blepharoplasty Surgery

• Mainly for cosmetic correction of patient's eye bag.

Two common Surgical methods:

• Anterior Approach
  - Excision of (skin, orbicularis muscle, orbital fat)+Reconstruction of lid crease
• Posterior Approach
  - Excision of orbital fat only

Management of Stroke: Current Updates

15th January 2013

Recent Trend in Treatment of Acute Thrombotic Stroke

Dr. Kwok Ching Kwong
Specialist in Neurosurgery

The incidence rates of first-ever stroke in Hong Kong decreased slightly from 13.3 (2000-01) to 10.6 (2006-07) per 1,000 population among people aged 65 and above. The declining trend could be related to the increasing awareness in primary and secondary preventions of stroke in the last decade. More effective drugs in controlling hypertension, hyperlipidaemia, diabetes mellitus are introduced. Moreover, the use of anti-platelets drug and anticoagulant in reducing clot formation are pivotal in prevention. At the same time, change of life style such as cessation of smoking, weight reduction and regular exercise has great impact in reducing incidence of stroke. Other factor such as the introduction of more effective neurological intervention also brings about the change.

Extracranial-intracranial EC/IC arterial bypass surgery was abandoned in the 80's due to poor outcome in stroke prevention. The idea was rekindled by the Japanese JET study in 2005. However, more recent Carotid Occlusion Surgery Study COSS in 2011 was stopped early by the US National Institutes of Health due to unfavorable outcome.

Intravenous IV thrombolytic therapy in the first 3 hours after stroke onset however, showed promising result. The NINDS Trial started in 1995 followed by ECASS I,II,III and IST-3 have demonstrated effectiveness of tissue plasminogen activator tPA to salvage the ischaemic penumbra and restore cerebral function. More than 50% recanalization rate was achieved in dissolving clot in major cerebral vessel with acceptable haemorrhagic rate of 6.4%. Transcatheter intra-arterial IA injection of thrombolytic drug such as urokinase in PROCT I and II trials showed improvement of recanalization rate to >60% with extended therapeutic window to 6 hours. However, the haemorrhagic rate was >10% which was much higher than IV treatment.

Currently, intravenous (IV) tissue-type plasminogen activator (tPA) has become a landmark development for treatment of acute thrombotic stroke and has been endorsed as a class IA level of evidence intervention. This strategy has the advantage of being relatively easy and rapid to initiate and does not require highly specialized equipment or technical expertise. Mechanical thrombolytic methods on the other hand, can remove a clot in a matter of minutes, whereas pharmaceutical thrombolytics, even those delivered intra-arterially, may take as long as 2 hours to dissolve a thrombus. Furthermore, the initial clot load in the cerebral circulation dictates the efficiency of recanalization. Larger volume and longer length of clot within the vascular tree prevent penetration of the pharmaceutical agent to act on the distal segment of occlusion. As a result, the recanalization rate of IV tPA for proximal arterial occlusion range from only 10% for internal carotid artery (ICA) occlusion to 30% for proximal middle cerebral artery (MCA) occlusion. Clot retrieval by mechanical method is deemed necessary when the clot load is high.

Attention has been drawn to a microcatheter-delivered, highly-flexible and fully-retrievable stent-like device, specifically designed for intracranial thrombolectomy. There

are two main categories that show promising results without the use of chemical lytic agent as adjunct: 1) endovascular thrombectomy, 2) endovascular thromboaspiration. Such methods have demonstrated higher recanalization rate and can extend the treatment widow beyond 6-8 hours. The device can navigate beyond the bifurcation of MCA and provide better clot engagement with a lower likelihood of clot fragmentation and distal embolism when compared with clot maceration technique.

Newer revascularization concepts like the use of stent-based thrombectomy devices achieve revascularization rates of 90%; however, there still remains a mismatch between revascularization, short term and long term clinical outcomes. More research and testing are required.

Imaging in Acute Stroke – from Basic to Advanced

Dr Poon Wai Lun, William
Specialist in Radiology

Cerebraovascular disease is a major cause of mortality and morbidity in Hong Kong. More than 3400 patients died of acute stroke every year. For those who survived the acute episode, 71% of them were unable to return to their job. The standard therapy for acute ischaemic stroke is intravenous thrombolysis. With the advancement of Interventional Neuroradiology techniques, intraarterial thrombolysis or mechanical thrombectomy now becomes the only hope for those who present outside the therapeutic window of 3 to 4.5 hours of intravenous thrombolysis.

To achieve the best therapeutic outcome, we need state-of-the-art neuroimaging techniques to select those patients who are eligible for intravenous or intraarterial treatment. There are four critical questions that current acute stroke imaging need to answer: (1) Is there haemorrhage? (2) Is there intravascular thrombus that can be targeted for thrombolysis? (3) Is there an infarct core and how big is it? (4) Is there a salvageable ischaemic penumbra? A plain CT brain study is the single best imaging modality that answer question 1. To address question 2, we need CT angiogram or MR angiogram. For questions 3 and 4, we rely on CT perfusion study or MR perfusion/diffusion study. The infarct core can be distinguished from the salvageable brain tissue by their significant reduction in cerebral blood flow (CBF) and cerebral blood volume (CBV) in CT perfusion scan. In MRI study, the infarct core will demonstrate evidence of diffusion restriction and prolongation of Tmax which is a measure of vascular transit in perfusion study. In addition, the time sequence of occurrence of signal change in diffusion-weighted and fluid-attenuated inversion recovery (FLAIR) imaging sequences in MRI helps to estimate the time of onset of acute ischaemic stroke which could be unknown clinically. Clinicians can therefore be more confident in deciding whether or not to given thrombolytic therapy even he or she does not know when the stroke was onset. After the acute stroke episode, perfusion imaging with acetazolamide challenge will be useful to determine the significance of any residual carotid stenosis, by calculating the cerebrovascular reserve.

In conclusion, advanced acute stroke imaging now serves as an indisputable guide in thrombolytic or mechanical thrombectomy treatment, so that we are able to maximize the benefit and minimize the complication in our patients.

HOSPITAL UPDATES

新春團拜暨醫院認證嘉年華
(19/02/2013)

聖保祿醫院今年參與澳洲醫療服務標準委員會(ACHS)的醫院認證計劃，並安排於2013年5月13至16日進行實地差距分析(Consultancy Gap Analysis)。全醫院上下正密鑼緊鼓地進行準備工作，為鼓勵同事以正面積極的態度及輕鬆的心情面對，院方特別於2月19日(年初十)舉行蛇年新春團拜暨醫院認證嘉年華，讓大家歡聚一堂，加強彼此溝通。嘉年華設有三個有獎攤位問答遊戲，內容與醫院認證相關，寓遊戲於學習，以輕鬆手法加強前線同事對醫院認證的認識。

醫院管理層向全院同事團拜。

有獎攤位問答遊戲吸引同事熱烈參與。

不少前線同事抽空參與團拜，氣氛熱鬧。

醫院認證經驗分享講座

(18/02/2013 & 22/03/2013)

為加強同事對醫院認證的認識及增強同事的信心，本院質素及風險管理部安排了兩次講座，邀請了來自醫院管理局的資深管理人員、醫生及護士主講，三名嘉賓均是ACHS(HK)評審員，他們前來本院向近百名同事分享醫院認證的寶貴實踐經驗。兩場講座分別於2月18日及3月22日舉行，分別由醫管局九龍東醫院聯網總監雷操奭醫生，及明愛醫院內科及老人科顧問醫生陳耀奇和該院高級護士長(質素及安全)歐陽月琼女士主講，參與同事獲益不少，為本院進行醫院認證注下強心針。

雷操奭醫生(右三)與本院管理層合照。

本院執行董事張柱見修女頒發紀念狀予雷操奭醫生。

本院醫務總監何兆煒醫生頒發感謝狀予陳耀奇醫生。

本院醫務總監何兆煒醫生頒發感謝狀予歐陽月琼女士。

雷操奭醫生分享他作為ACHS評審員的經驗。

陳耀奇醫生分享明愛醫院取得醫院認證的成功經驗。

近百名同事參與講座。

HOSPITAL ACTIVITIES

2013四旬期退省活動

(18/03/2013)

醫院周年四旬期退省活動已於3月18日(星期一)在上水聖保祿樂靜院舉行，時間由上午九時至下午四時，出席人數共有四十一人，神師為蔡惠民神父，今次退省活動的主題為耶穌的信德。

今年的退省內容豐富，包括頌唸玫瑰經、神父專題講道、個人靜默及祈禱、修和聖事、感恩聖祭和拜苦路等。樂靜院環境清幽，使人心曠神怡，是親近天主、與主談心的好地方，在靜的環境中與主相遇，洗刷心靈的累贅。

蔡神父在上午的講道中帶出耶穌的信德，在耶穌身處的環境中有不同派別的人，他們各自對信仰有不同的看法，而耶穌在他們面前受到不同程度的挑戰和考驗；在山園祈禱中，耶穌面對困難，流露了對天父的服從及願意接受天父交給他的苦路，而新生命和復活的榮光在苦路的盡頭等待他。在下午的講道中，蔡神父帶出耶穌的誘惑和如何對抗誘惑，魔鬼嘗試令耶穌離開天父的旨意和計劃，而我們基督徒必須穿上天主的全副武裝以對抗誘惑（弗6:13-18），那是天主忠於承諾，照顧祂的子民，永不改變這態度及承諾。

整個退省在感恩的氣氛中完成，感謝天主的恩賜，感謝樂靜院為我們預備了美味的食物，感謝神父在百忙中抽空來為我們主持退省，更感謝各禮儀人員願意付出及服務，祝願有否參加退省的同事也蒙上主的祝福，共沐主恩！主佑各位！

主內平安！

牧靈部

INTRODUCTION
Of New Faces

Mr. Denis Leung
General Manager

In the past two months since I joined St. Paul's Hospital, I have met with quite a few colleagues during my orientation and gained useful insights into the workings of one of Hong Kong's leading hospitals. I am thankful for the warm reception and the cooperation extended to me thus far.

For those whom I did not have the chance to meet, I appreciate the opportunity to introduce myself here for the first time. I was trained as a bio-medical engineer in Canada and had gained extensive working experience in the medical industry before joining Siemens Hong Kong in 1988 to help establish their new medical division. I had enjoyed a long career with Siemens and in 2002 I was appointed CEO, a role that assumed overall responsibilities for the entire operation in Hong Kong and Macau.

I am delighted that my appointment with St Paul's Hospital has brought me back to a field with which I feel most connected. I have witnessed phenomenon growth of SPH in the last years and with the massive construction work of our new block well underway, I look forward to playing a key role in its future development and continued success. It is my belief that our collective efforts and commitment to excellence will see us through many exciting challenges and opportunities ahead. We will strive to fulfill our social responsibilities in delivering outstanding services to the local communities and to elevate SPH to a new level of medicare provider in the 21st century.

Hi, this is Alan Chan, it's my pleasure to join St. Paul's Hospital since November 2012 as Manager of Material Management Department. I've been serving in commercial sector for years and most of my working exposures are majorly focus in Supply Chain and Logistics scopes in Asia. In view of the dynamic challenges, I was intensified with further training in e-commerce area as well as logistics system in Australia and Hong Kong to cater the fast changing environment. Over my years of services, I've been participated in couple of business enhancement projects in supply chain integration and process mapping in EMS and retail sectors, as well as sustaining the operation efficiency with the value chain activities.

Although I am not from Healthcare sector, I would like to have my logistics background to be teamed up together with your specialist to enhance the service in more effective way especially in the area of healthcare material management for a better total service level and cost effective mechanism. In addition, I am considering myself a continuous learner and your expertise input for sure will inspire further synergy for an integrated enhancement to cater for the dynamic challenges we are encountering. For sure we will cohere together to benefit St Paul's Hospital with all our effort and participation in the years to come.

Mr. Alan Chan
Manager,
Material Management Department

Dr. Chan Kin Ming, Kevin
Specialist in Otorhinolaryngology

Hi Everyone. I am Chan Kin Ming, known to my friends as Kevin. It is my great honor to work with all of you as the staff specialist in otorhinolaryngology, or ENT if that's too long for you since 1st February. Before I came, I was the Associate Consultant of the Department of Otorhinolaryngology Queen Mary Hospital. Besides general ENT training, I had my overseas training in sleep disorder breathing in particularly surgery for patients with snoring and obstructive sleep apnea. Moreover, I have special interest in Otology especially surgery for hearing. It is always of great pleasure to see improvement in patients with hearing impairment with great satisfaction after surgery. In my free time, I enjoy sports a lots in particularly badminton, water sports and scuba diving.

Coming to his new page of my career, I am really excited and looking forward to developing and enhancing the ENT service in St Paul's Hospital. Thanks to everyone for being so welcoming, and I look forward to working with all of you.

I am Dr. Jeriel Chung Kai Lee, the new radiology resident specialist. My name "Jeriel" is of Hebrew origin, pronounced as "Jeri-el". It is my great honor to join the St. Paul's Hospital community and to work alongside my new and old colleagues.

Since graduating from the University of Hong Kong, I worked at Pamela Youde Nethersole Eastern Hospital with rotations to Ruttonjee Hospital and Tung Wah Eastern Hospital. My subspecialty is musculoskeletal imaging. A few years ago, I had the opportunity to take a sabbatical at University of California San Diego, which is renowned for musculoskeletal imaging.

It has only been a few weeks since I started working here. I am adjusting to the new environment, workflow and the equipments in my department. As communication is a very important part of my job, please feel free to contact me anytime for case discussion. I look forward to working with you.

Dr. Jeriel Lee
Specialist in Radiology

Dr. Yim Wai Ting, Veronica
Specialist in Emergency Medicine

I am Dr. Yim Wai Ting Veronica, a specialist in emergency medicine. I joined St Paul's Hospital as a resident doctor since March 2013. It's my great honor to become one of the team members in the hospital.

Having been working in the Accident and Emergency Department of Prince of Wales Hospital for 15 years, I acquired the knowledge and skills in managing a wide range of acute clinical conditions. By working with the team of medical and nursing staff at St Paul's Hospital, I'm sure I can apply my clinical experience to serve the patients here, providing timely and quality patient care.

Working in the private sector is both exciting and challenging to me. I know I can adapt to the new working environment very soon with the help of the friendly colleagues here.

I look forward to working with you in the years to come.